



วารสารมหาวิทยาลัยนเรศวร  
Naresuan University Journal

# วิทยาศาสตร์และเทคโนโลยี Science and Technology

(ชื่อเดิม: วารสารมหาวิทยาลัยนเรศวร)

ปีที่ 23

มกราคม-เมษายน  
ฉบับที่ 1

ระบบวารสารออนไลน์ [www.journal.nu.ac.th](http://www.journal.nu.ac.th)

โทร. 0 5596 8835 โทรสาร. 0 5596 8826 บันทึกวิทยาลัย มหาวิทยาลัยนเรศวร







## บทความปริทัศน์

### Periprosthetic Joint Infection of Hip and Knee: A Review of Current Concepts

ปิติ รัตนปรีชาเวช.....1

## บทความวิจัย

### Who should teach rheumatology to medical students, a rheumatologist or an internist?

ปรุพงศ์ ไตรวิวัฒน์ รวิสุด เตียววิศเรศ นันทนา ชุมช่วย และศุภลสิทธิ์ พรรณารุโณทัย.....22

### Question-Answering Approach to 3D Information Retrieval System

ทวีศักดิ์ สังข์ปรีชา และภัทรภร สังข์ปรีชา.....30

### Sustainability of Alternative Energy for Organic Rankine Cycle Power Plant in Thailand

นัฐพร ไชยญาติ.....45

### The Viewpoints of Sustainable Agriculture within the System Approach in Agriculture

ภัทรพงษ์ เกริกสกุล และประมุข ศรีชัยวงษ์.....63

### อาหารอย่างง่ายจากสารละลายธาตุอาหารสำหรับปลูกพืชโดยไม่ใช้ดินเพื่อการเพาะเลี้ยงเนื้อเยื่อม่วงเทพรัตน์ และหนุ่ยหวาน

กิตติศักดิ์ โชติกเดชาณรงค์.....74

### ปริมาณโลหะหนักที่สะสมในผักบุ้ง (*Ipomoea aquatica* Forsk) ที่ปลูกในแม่น้ำท่าจีน

วิริยาภรณ์ รัตนไพบูลย์, นฤชิต ดำปิ่น และเกษม จันทร์แก้ว.....82

### คุณสมบัติดินที่มีผลต่อการเพิ่มขึ้นของพื้นที่ป่าชายเลนบริเวณโครงการศึกษาวิจัยและพัฒนาสิ่งแวดล้อมแหลมผักเบี้ย อันเนื่องมาจากพระราชดำริ จังหวัดเพชรบุรี

ผุสดี สุขพิบูลย์, สามัคคี บุญยะวัฒน์ และนฤชิต ดำปิ่น.....94

### การพัฒนาชุดกิจกรรมการเรียนรู้ เรื่องทฤษฎีบทพีทาโกรัสที่ส่งเสริมความสามารถในการเชื่อมโยงสำหรับนักเรียน ชั้นมัธยมศึกษาปีที่ 2

ศิรินททิพย์ อิศาระ และบุญญา เพียรสุวรรณค์.....110

### การศึกษาปัจจัยในการกีดกันงานด้วยเมตมิต APMT1604PDER-M2 ที่มีผลต่ออายุการใช้งานของคมตัดและความเรียบผิว

บัญญัติ พันธุ์ประสิทธิ์เวช, ปฏิพัทธ์ หงษ์สุวรรณ และวิชัย จันทรักษา.....121

### การปรับปรุงประสิทธิภาพโดยรวมในกระบวนการท่อไม่ผ่า

ธเนศ รัตนวิไล และวุฒิไกร ศรีสุข.....133

### การวิเคราะห์ความเสี่ยงระดับปฏิบัติการสำหรับธุรกิจขนาดเล็ก กรณีศึกษา

รัชชานา สีนวาลัย และนฤมล ดาววี.....142





## Periprosthetic Joint Infection of Hip and Knee: A Review of Current Concepts

Piti Rattanaprichavej

Department of Orthopaedic, Faculty of Medicine, Naresuan University, Phitsanulok, Thailand 65000

Corresponding author. E-mail address: pt-rp@hotmail.com

### Abstract

Total joint arthroplasty is a successful and recently developed procedure performed on an increasing number of patients. However, periprosthetic joint infection (PJI) is a calamitous complication of this operation, the incidence of which is 1-2%. Different investigators have defined numerous definitions for this complication, but the Musculoskeletal Infection Society (MSIS) definition of PJI has been most widely used. Management of PJI ranges from antibiotic suppression alone to two-stage revision surgery depending on the onset and duration of infection. Currently, investigation focuses on early diagnosis of PJI by multiple indicators in order to diminish the severity of this complication. Fungal PJI and culture-negative PJI are even more rare but much difficult to treat than typical PJI. Knowledge of the association between PJI and bacterial biofilm appears to be an emerging concept for the diagnosis and management of PJI.

**Keywords:** Periprosthetic joint infection, PJI, infected TKA, infected THA, revision TJA

### Introduction

One of the most successful and effective procedures, total joint arthroplasty (TJA) improves quality of life, increases range of motion, restores joint function, and relieves patients' pain symptoms. Periprosthetic joint infection (PJI) is one of the most catastrophic complications following TJA surgery. This complication is one of the most common reasons for revision surgery in TJA patients. The estimated incidence of PJI is around 1-2% for all TJA surgeries. Even though the incidence of PJI is considered small, the numbers of patients with this complicate will increase with the growth of this procedure. PJI should be ruled out in all patients with a history of painful arthroplasty, especially in patients with early loosening within the first few years after the operation (Ailabouni Ramez, & Hooper Gary, 2015, pp. 1-8). Healthcare data show that the rate of PJI is 1.55% within the first two years, with an additional 0.46% annually over the following two to

ten years (Garvin, & Konigsberg, 2011, pp. 1167-1175).

PJI is often a devastating complication because it may occur as a result of any pathogen and lack of gold standard criteria for diagnosis. Treatment for PJI ranges from antibiotic suppression alone to two-stage prosthesis exchange, depending on the onset and duration of PJI. Because its onset and duration will determine the method of treatment, early detection of PJI is the cornerstone for management. This article will review about a latest laboratory investigation and a contemporary treatment option for PJI.

### Definition

Before addressing PJI diagnosis and management, we should start with the most basic question: "What is PJI?" Many articles have tried to define PJI (Della Valle, et al., 2010, pp. 760-770; Minassian, Osmon, & Berendt, 2014, pp. i29-35; Osmon, et al., 2013, pp. e1-e25), but the most acceptable



definition comes from the Musculoskeletal Infection Society (MSIS) 2011 (Parvizi, et al., 2011, pp. 2992-2994). Diagnostic criteria for PJI were divided into 2 major criteria and 6 minor criteria by MSIS.

In August 2013, an international consensus meeting on PJI was held by a large group of experts.

The consensus groups (Zmistowski, et al., 2014, pp. 77-83) modified MSIS diagnostic criteria by removing the presence of purulence in affected joint and adding the leukocyte esterase test as a new minor criterion (Table 1).

**Table 1** A new PJI definition by International consensus workgroup 2013 (Zmistowski, et al., 2014, pp. 77-83)

A definite PJI exist when one of major or three of minor criteria are met	
Major criteria	Minor criteria
A sinus tract communicating with the joint	Elevated serum ESR and CRP
Two positive periprosthetic cultures with phenotypically identical organism	Elevated synovial WBC count or ++ change on leukocyte esterase strip test
	Elevated synovial PMN %
	A single positive culture
	Positive histological analysis of periprosthetic tissue

#### Diagnosis of PJI

##### History and Physical Examination

Evaluation of a patient with suspected PJI should include a thorough history and physical examination. Clinical signs and symptoms should not be outweighed by any modern investigation. Acute onset or chronic pain in any replaced joint at any time after

replacement, particularly in the absence of a pain-free interval, should be suspected for PJI. Suspicious clinical presentations of PJI are summarized below (Table 2). Patient with these suspicious clinical signs should be suspected for PJI until it is ruled out (Garvin, & Konigsberg, 2011, pp. 1167-1175; Osmon, et al., 2013, pp. e1-e25; Zmistowski, et al., 2014, pp. 77-83).

**Table 2** Suspicious clinical presentation for PJI

History	Physical exam
Persistent pain or stiffness in the replaced joint and any of the following: -Recent bacteremia (<1yr) -Metachronous PJI -Prior infection of the joint -Superficial surgical site infection -Immunocompromised host -Multiple surgery on the same joint -Skin disorder (psoriasis, skin ulceration)	Wound dehiscence Joint warmth, redness or swelling
<b>Plain Radiograph</b> Signs of loosening of a previously well-fixed prosthesis and osteolysis around the prosthetic	component, particularly within 5 years postoperative, should be suggestive for PJI (Garvin, & Konigsberg, 2011, pp. 1167-1175). Subperiosteal elevation or





transcortical sinus tracts may also be found in the plain radiograph of PJI patients (Zmistowski, et al., 2014, pp. 77-83). However, it should be kept in mind that plain radiographs are generally normal in PJI cases.

#### **White Blood Cell Count and Differential**

Serum white blood cell (WBC) count and neutrophil differential are common basic lab tests to detect general infectious disease. There are conflicting results for the cut-off values of serum WBC count and neutrophil percentage. A recent study (Toossi, Adeli, Rasouli, Huang, & Parvizi, 2012, p. e51) showed that the cut-off value for PJI diagnosis with serum WBC count at  $>7,800$  cells/ $\mu\text{L}$  had a 55% sensitivity and 66% specificity, whereas the cut-off value of the neutrophil differential at  $>68\%$  had a 52% sensitivity and 75% specificity. Serum WBC count and analysis has little role in the diagnosis of PJI (Toossi, et al., 2012, p. e51; Zmistowski, Restrepo, Huang, Hozack, & Parvizi, 2012, pp. 1589-1593).

Synovial WBC count and the polymorphonuclear cells (PMNs) differential have been used as a standard diagnostic tool for PJI. The optimal cut-off values for synovial WBC count and PMN percentage in diagnosis of PJI are still under debate. In late, chronic PJI, suggested cut-off values for synovial WBC count and PMN differential range from 1,100 to 3,000 cells/ $\mu\text{L}$  and from 60 to 80%, respectively (Christensen, et al., 2013, pp. 2081-2087; Parvizi, & Gehrke, 2014, p. 1331; Zmistowski, et al., 2014, pp. 77-83). In the first six-weeks postoperative, these cut-off values should be adjusted, because in the early postoperative period, the inflammation process might interfere with the synovial WBC and PMN percentage. The use of a cut-off value of 3,000 cells/ $\mu\text{L}$  will lead to unnecessary reoperations during this early postoperative period. The optimal threshold for

diagnosing PJI in the early postoperative period is synovial WBC  $>27,800$  cells/ $\mu\text{L}$  and a PMN differential  $>89\%$  (sensitivity 84%, specificity 99%) (Bedair, et al., 2011, pp. 34-40). Recent data have suggested that synovial total neutrophil count (TNC), calculated by  $\text{TNC} = \text{WBC count} \times \text{PMN percentage}$ , may be more reliable indicator for diagnosing PJI than synovial WBC count and PMN percentage alone (Christensen, et al., 2013, pp. 2081-2087).

The Society of Unicondylar Research and Continuing Education recommended that the cut-off value for PJI diagnosis in patients after unicompartment knee arthroplasty should be 6,200 cells/ $\mu\text{L}$  for synovial WBC and 60% for PMN differential, with a 90% sensitivity and 95% specificity (Diagnosis of periprosthetic joint infection after unicompartmental knee arthroplasty, 2012).

#### **Erythrocyte Sedimentation Rate and C-Reactive Protein**

The introduction of serum erythrocyte sedimentation rate (ESR) and serum C-reactive protein (CRP) as one criterion in the diagnosis of PJI emphasizes the need for precise standard definitions and thresholds. When combined together, serum ESR and serum CRP have sensitivity and specificity varying from 90-98% and 60-90%, respectively, depending on their cut-off values (Alijanipour, Bakhshi, & Parvizi, 2013, pp. 3186-3195; Lee Kyung-Jae, 2014, pp. 1-5; Ronde-Oustau, et al., 2014, pp. 217-220). The international consensus group proposed standard thresholds of 30mm/hour for ESR and 10 mg/L for CRP in late, chronic PJI (Parvizi, & Gehrke, 2014, p. 1331; Zmistowski, et al., 2014, pp. 77-83). For acute PJI, the consensus group agreed on no standard threshold for ESR and a threshold of 100 mg/L for CRP (Parvizi, & Gehrke, 2014, p. 1331). There were no



distinction between the thresholds for total knee arthroplasty (TKA) and total hip arthroplasty (THA).

Unfortunately, these serum ESR and CRP are not consistently reliable because of their high sensitivity but lack of specificity; these markers might be affected by age, sex, and medical comorbidities of the patient (Lee Kyung-Jae, 2014, pp. 1-5; Liu, Saleh, Klika, Barsoum, & Higuera, 2014, pp. 1880-1883). For these reasons, synovial CRP was thought to be a more specific marker than serum CRP in diagnosing PJI. Recent studies have proposed that a cut-off value of synovial CRP at 5.4-6.6 mg/L could increase the specificity of PJI diagnosis to 85-90% (Ronde-Oustau, et al., 2014, pp. 217-220; Tetreault, Wetters, Moric, Gross, & Della Valle, 2014, pp. 3997-4003), but the true standard threshold and the applicability of this test are still under investigation (Cummins, 2014, pp. 4004-4005).

#### **Leukocyte Esterase Reagent Strip Test**

The leukocyte esterase reagent (LER) strip test, also known as the urine strip test, has been used for 30 years to detect urinary tract infection. The color of the LER strip will change as a result of chemical reaction with the leukocyte esterase enzyme. Leukocyte esterase is an enzyme produced in response to the inflammation process by neutrophils that have been recruited into the site of infection. The LER strip test has 80% sensitivity and 100% specificity in detecting PJI (Parvizi, Jacovides, Antoci, & Ghanem, 2011, pp. 2242-2248). The LER strip test has the benefit of being simple and inexpensive. It provides real-time results and has the ability both to rule in and rule out PJI. Its utility is limited if blood or debris in synovial fluid renders the test unreadable (Wetters, et al., 2012, pp. 8-11).

Because of its efficacy and applicability, the international consensus workgroup made the LER

strip test a new additional, minor criterion for detecting PJI (Zmistowski, et al., 2014, pp. 77-83).

#### **Frozen Section**

There is a long-standing debate regarding the most suitable threshold for PJI diagnosis in frozen section, 5 or 10 PMN per high power field (HPF). A recent meta-analysis (Zhao, et al., 2013, pp. 913-917) revealed no difference in sensitivity (84%) between 5 and 10 PMN/HPF used as indicators, but specificity was significantly improved to 100% when 10 PMN/HPF was used as threshold (vs. 96% when 5 PMN/HPF was used). However, the workgroup decided to use 5 PMN/HPF as the conventional cut-off for detecting PJI in both acute and chronic situations (Parvizi, & Gehrke, 2014, p. 1331).

#### **Culture**

Identification of the infective organism is a crucial step in the diagnosis and management of PJI. However, there is still no consensus regarding the most suitable method for obtaining cultures. In an analysis of 117 revisions with 30 PJI comparing between tissue and swab cultures, swab culture had both lower sensitivity (70% vs. 93%) and lower specificity (89% vs. 98%) than tissue culture (Aggarwal, Higuera, Deirmengian, Parvizi, & Austin, 2013, pp. 3196-3203). This finding supports the long-held belief that swab cultures are not as effective as tissue cultures in diagnosing PJI.

Tissue or fluid sampling from the prosthesis-bone interface is preferable; 5-6 samples should be collected to maximize sensitivity and specificity (Zmistowski, et al., 2014, pp. 77-83). In the case of a dry-aspiration scenario, a percutaneous interface biopsy may have a role to play for the preoperative diagnosis of PJI (Corona, et al., 2012, pp. 1281-1286).





### Interleukin-6

Interleukin-6 (IL-6) is an inflammatory cytokine secreted by activated macrophages, monocytes, and T cells in response to the inflammation process and that induces the production of CRP. The advantage of IL-6 as a diagnostic indicator is that it responds more rapidly to inflammation and more quickly returns to normal level compared to other biological markers for inflammation (Elgeidi, Elganainy, Abou Elkhier, & Rakha, 2014, pp. 2591-2595).

Both serum and synovial IL-6 were thought to be the best laboratory markers for predicting PJI (Elgeidi, et al., 2014, pp. 2591-2595; Lenski, & Scherer, 2014, pp. 1105-1109). With a threshold of 10.4 pg/ml, serum IL-6 has 100% sensitivity and 90.9% specificity for detecting PJI (Elgeidi, et al., 2014, pp. 2591-2595). Synovial IL-6 less than 10,000 pg/ml, meanwhile, makes PJI very unlikely (Lenski, & Scherer, 2014, pp. 1105-1109).

Even though IL-6 is not included in current diagnostic criteria for PJI, these promising results make IL-6 an outstanding laboratory test for PJI moving forward. Many published studies have tried to create standardized thresholds and have tried to establish the utility of IL-6.

### Sonicate Fluid Culture

Explants sonicate fluid culture (SFC) during a revision procedure has been shown to increase the rate of isolating pathogens without increasing the likelihood of contamination. A prospective study of 59 patients found that SFC has a higher sensitivity (91%) than CRP (83%) and tissue culture (75%), but the specificity of SFC was lower than tissue culture (81% vs 100%) (Janz, et al., 2013, pp. 931-936). Routine use of SFC is not recommended; it must be limited to suspected or proven PJI patients

(by other testing) in which the preoperative culture does not yield a positive result and in which antibiotics have been given within 2 weeks (Zmistowski, et al., 2014, pp. 77-83).

### Other Biological Markers

Soluble urokinase-type plasminogen activator receptor (uPAR) is described as a forceful diagnostic tool for detecting sepsis. The uPAR is a glycoprotein produced during an inflammation and infection process. Serum-soluble uPAR showed potent and significant increase in PJI patients, along with a significant positive correlation with CRP and IL-6 (Galliera, et al., 2015, pp. 23-28).

Lipopolysaccharide-binding protein (LBP) is a polypeptide synthesized by the liver in response to inflammatory cytokines. This fact leads to the hypothesis that serum LBP could serve as a diagnostic tool for PJI. However, an in-vivo study demonstrated that serum LBP has a poor sensitivity and specificity (66% and 71%) for diagnosing PJI (Friedrich, et al., 2014, pp. 2201-2207).

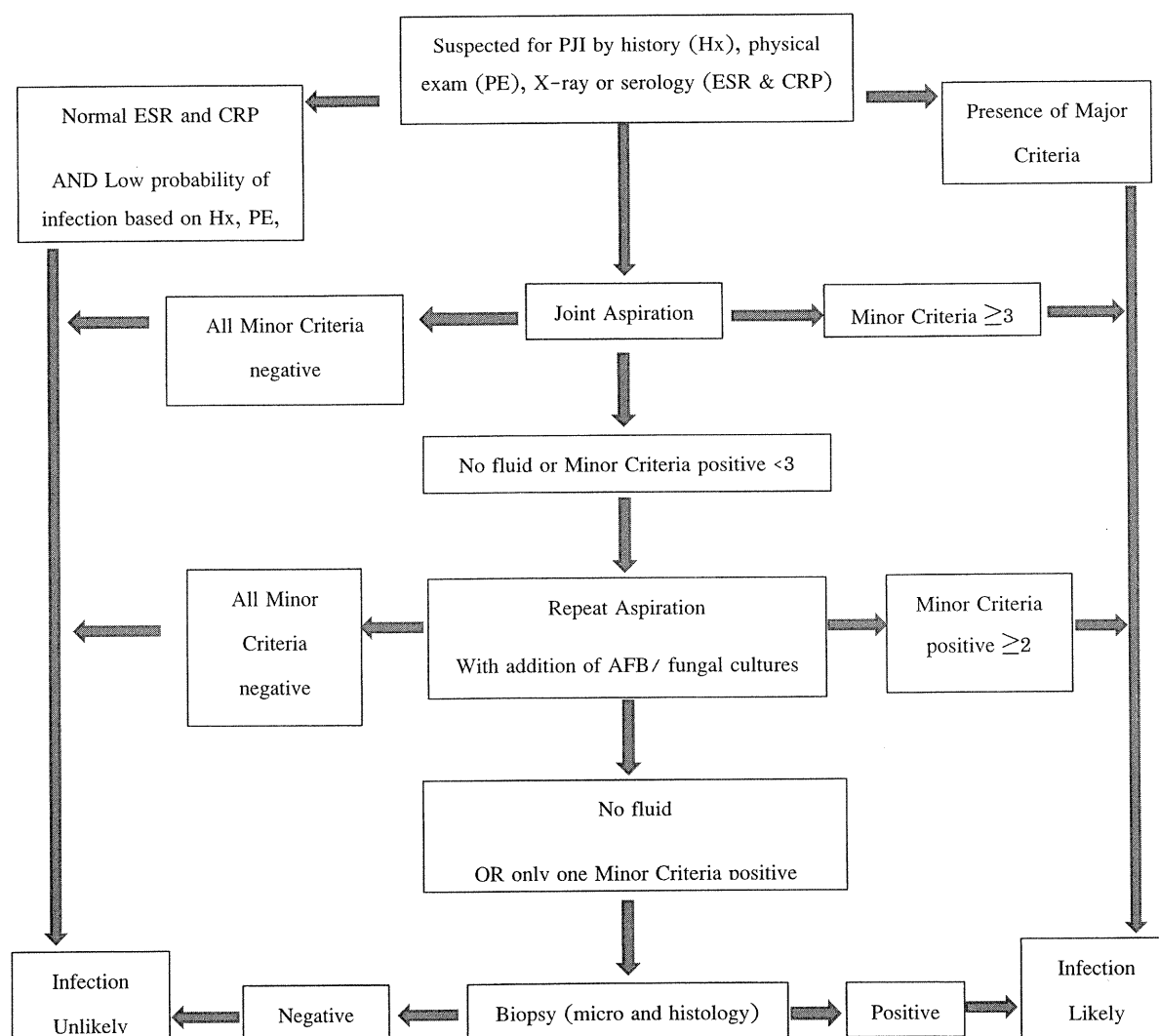
Alpha defensin is a peptide released by neutrophils in an infection. From preliminary reports, the alpha defensin immunoassay certainly does show promising results in diagnosing PJI with 100% sensitivity and 100% specificity, even based on a sample from a patient receiving antibiotics prior to the aspiration (Sheehan, 2015, pp. 204-205).

Early diagnosis and accurate isolation of pathogens are important steps to guide the treatment of PJI. Many investigators have tried to propose new investigations and to develop a new diagnostic tool to create a universal gold standard for detecting PJI. Only time will tell which are the best. The universally accepted threshold of commonly used laboratory tests are presented in Table 3, and the diagnostic approach for PJI is shown in Figure 1.



**Table 3** The threshold for the Minor diagnostic criteria (Parvizi, & Gehrke, 2014, p. 1331; Zmistowski, et al., 2014, pp. 77-83)

Criteria	Acute PJI (<90 days)	Chronic PJI (>90 days)
ESR (mm/hr)	No threshold was determined	30
CRP (mg/ml)	100	10
Synovial WBC count (cells/ $\mu$ L)	10,000	3,000
Synovial PMN (%)	90	80
Leukocyte esterase	+ or ++	+ or ++
Histological analysis of tissue	>5 PMNs/ HPF	>5 PMNs/ HPF



**Figure 1** Diagnostic approach for detect PJI

### Classification

The best-known and most-used classification of PJI is that of Segawa and Tsukayama (Segawa, Tsukayama, Kyle, Becker, & Gustilo, 1999, pp.

1434-1445). This classification categorizes PJI into four types (Table 4) depending on the onset and duration of symptoms. Treatment of each type is different, which will be discussed later.

**Table 4** Segawa and Tsukayama classification of PJI (Segawa, et al., 1999, pp. 1434-1445)

Type	Timing	Definition
1	Positive intraoperative culture	$\geq 2$ deep culture positive for the same organism obtained intraoperatively
2	Early postoperative infection	Infection $\leq 4$ weeks postoperatively
3	Acute hematogenous infection	Infection in a previously well-functioning TJA subsequent to bacteremia
4	Chronic infection	Infection $\geq 4$ weeks postoperatively with a more insidious clinical presentation

### Treatment

After diagnosis of PJI is made, there are many treatment options depending on the type of PJI and the onset and duration of the infection. The goals of treatment are a pain-free and functional replaced joint with the eradication of infection.

#### Antibiotic Suppression

Antibiotic suppression is not a first choice for treating PJI. It is only indicated for some patients who are too frail to withstand an operation and whose infection is caused by a low-virulence organism that is susceptible to antibiotics (Parvizi, Adeli, Zmistowski, Restrepo, & Greenwald, 2012, p. e104). Treatment with long-term suppressive antibiotics alone may be the best treatment option for such patients, because they have a low risk of devastating implant failure (Ailabouni Ramez, & Hooper Gary, 2015, pp. 1-8). However, there is still no consensus regarding which antibiotic is the most appropriate and for how long suppressive therapy should be administered (O'Toole, et al., 2014, pp. 115-118).

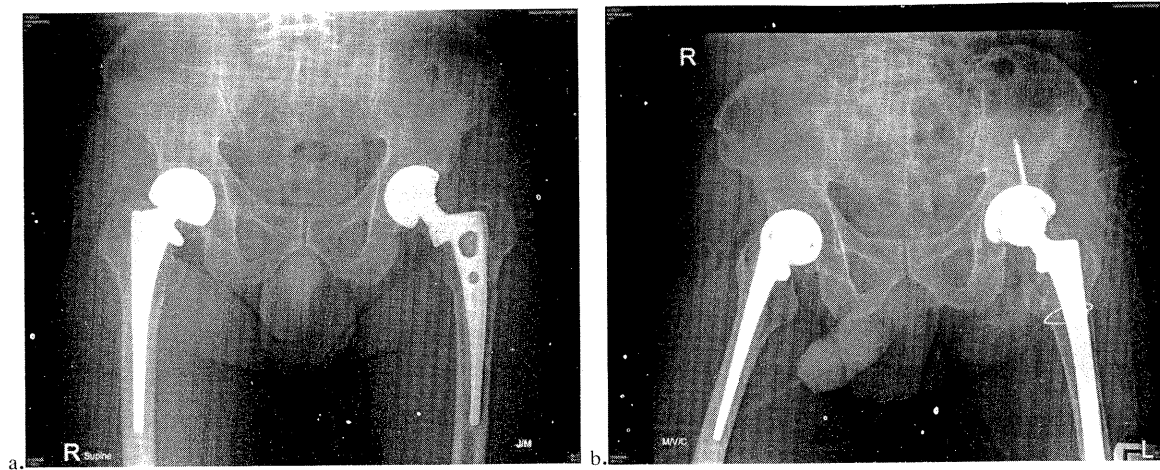
#### Irrigation and Debridement with Prosthesis Retention

Irrigation and debridement with prosthesis retention (IDPR) is suitable treatment option for early and hematogenous postoperative infection in which symptoms have lasted fewer than three weeks (Haasper, et al., 2014, pp. 100-103). Presence of sinus tract, PJI caused by a high-virulence pathogen,

and presence of a loose implant are contraindications for IDPR (Haasper, et al., 2014, pp. 100-103; Triantafyllopoulos, et al., 2014). Thorough debridement, copious irrigation, exchange of all modular components, and collection of multiple cultures should be meticulously performed (Chen Antonia, & Rao Nalini, 2012, pp. 236-246). IDPR has a success rate between 50 and 70% in acute PJI (Shanmugasundaram, Ricciardi, Briggs, Sussmann, & Bostrom, 2014, pp. 36-44). Furthermore, there is evidence that failed IDPR may compromise the results of subsequent two-stage revision surgery (Sherrell, et al., 2011, pp. 18-25).

#### One-Stage Revision Surgery

One-stage revision surgery was originally described by Buchholz et al. in the 1970s and is widely used among European surgeons for treating PJI (Hansen, et al., 2013, pp. 3214-3222). The success rate of this technique ranges from 55% to 90% in both acute and chronic PJI (Hansen, et al., 2013, pp. 3214-3222; Shanmugasundaram, et al., 2014, pp. 36-44; Zeller, et al., 2014, p. e1). Unfortunately, little data support the applicability of the one-stage exchange technique outside of THA or without antibiotic-impregnated cement (Hansen, et al., 2013, pp. 3214-3222; Manner, 2013, pp. 3223-3224; Zeller, et al., 2014, p. e1). One-stage exchange arthroplasty may be a reasonable treatment option in patients with known, isolated, and low-virulence pathogens that are susceptible to an available antibiotic (Figure 2).



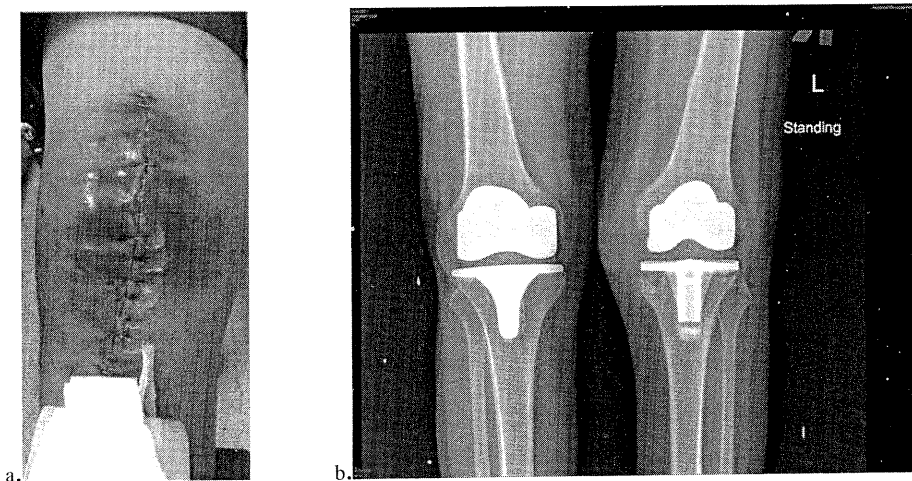
**Figure 2** One-stage revision arthroplasty (a) A preoperative anteroposterior(AP) film of patient with the diagnosis of acute hematogenous PJI of left hip. (b) After treated by one-stage exchange arthroplasty.

Patients with septicemia, sinus tract, poor soft-tissue coverage and culture-negative PJI are contraindicated for one-stage revision (Lichstein, et al., 2014, pp. 108-111). To the best of my knowledge, no randomized, controlled trial has demonstrated better outcomes for one-stage over two-stage revision surgery.

#### Two-Stage Revision Surgery

Currently, two-stage revision arthroplasty is considered the standard treatment for chronic PJI, particularly in North America. Insall was first to describe a two-stage exchange procedure for treating

PJI. The first stage begins with the removal of all components and foreign bodies from the joint, followed by extensive debridement, irrigation, and insertion of an antibiotic-laden cement spacer. In between the first and second stages, the patient receives an antibiotic for a period of time, selected based on a preoperative or intraoperative culture and sensitivity test. Reimplantation of implants in a second-stage operation is delayed until the wound has healed and the eradication of infection has been confirmed (Figure 3).



**Figure 3** Two-stage revision arthroplasty A 61 years old patients with the diagnosis of early postoperative PJI by MRSA infection, (a) a clinical presentation, (b) AP film, (c) after treated with first-stage implants removal and handmade-dynamic antibiotic spacers.

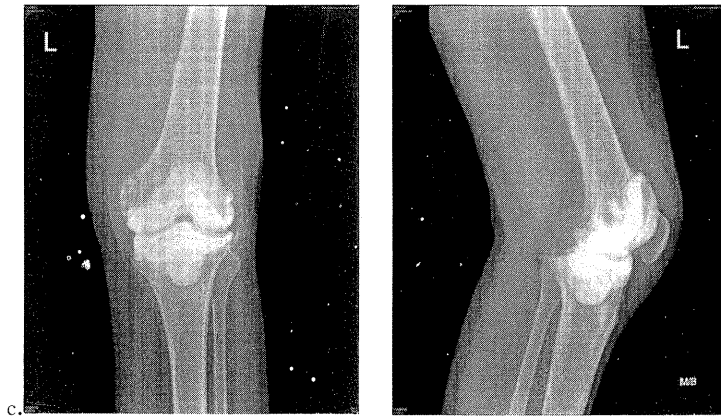


Figure 3 (cont.)

The antibiotics for the cement spacer must be soluble, thermodynamically stable, and have bactericidal properties. Usually, antibiotic cement is selected based on preoperative culture and sensitivity test. If the infecting organism is unknown, most experts in the literature recommend 4 gm of Vancomycin combined with 2–4 gm of Gentamicin per 40 gm of cement (Citak, et al., 2014, pp. 93–99; Kuzyk, et al., 2014, pp. 153–164).

Compared to a cement spacer, cement beads leave a joint in a pseudarthrotic state that will cause instability and pain, limit function, and complicate the second-stage surgery by soft tissue contracture (Kuzyk, et al., 2014, pp. 153–164).

Dynamic spacers provide better function than static spacers only in-between stages of two-stage revision arthroplasty. After reimplantation, dynamic spacers provide non-significant improvement to range of motion compared to static spacers (Citak, et al., 2014, pp. 93–99). However, the type of spacer—whether dynamic or static, handmade or custom-made does not affect the rate of infection eradication after both THA and TKA (Citak, et al., 2014, pp. 93–99; Kuzyk, et al., 2014, pp. 153–164).

There is a lack of consensus-accepted evidence regarding the optimal antibiotic, the ideal duration of antibiotic treatment, the proper route of antibiotic

administration, and the timing of the antibiotic holiday period before reimplantation (Restrepo, et al., 2014, pp. 104–107). Either a pathogen-specific antibiotic or a broad-spectrum antibiotic covering methicillin-resistance *Staphylococcus aureus* (MRSA) through intravenous therapy for 2–6 weeks is recommended (Kuzyk, et al., 2014, pp. 153–164; Osmon, et al., 2013, pp. e1–e25; Restrepo, et al., 2014, pp. 104–107). An optional treatment after the initial intravenous antibiotic is a pathogen-specific, highly bioavailable oral antibiotic.

The ideal timing for reimplantation is still controversial. In patients with recurrent infection, ESR and CRP levels were similar to those with successfully treated PJI, but synovial WBC count can identify persistent infection with a cut-off value of 3,000 cells/ $\mu$ L (same as PJI diagnosis) (Kuzyk, et al., 2014, pp. 153–164). Recently published literature has proposed that serum IL-6 <8 pg/ml can be regarded as a sign of the absence of infection and an indication for reimplantation (Hoell, et al., 2015, pp. 71–75).

In Europe, one-stage revision surgery is often preferred, because this single stage usually involves antibiotic-loaded cement. By contrast, the North America trend for over a decade has been toward the use of cementless technique. The eradication rate of



the two-stage revision procedure is 80–100% (Ascione, et al., 2015, pp. 30–36; Kuzyk, et al., 2014, pp. 153–164; Shanmugasundaram, et al., 2014, pp. 36–44; Stammers, et al., 2015, pp. 56–62), whereas the success rate of a one-stage revision using antibiotic-laden cement is 82–86% (Oe, et al., 2015, pp. 19–25), with a notably inferior result (56–59%) without antibiotic-loaded cement (Hansen, et al., 2013, pp. 3214–3222; Manner, 2013, pp. 3223–3224). Two-stage exchange arthroplasty is safer, but it has the disadvantage of

requiring a second operation, with an unknown waiting period in between stages. In 2014, a preoperative scoring system to determine the surgical strategy for PJI after THA was created according to various published criteria (Oe, et al., 2015, pp. 19–25), such as the patient's general condition, duration of infection, soft-tissue status, virulence of the pathogen, and degree of bone loss (Table 5). One-stage revision was recommended for THA patients with a score >9 points.

**Table 5** Preoperative scoring system to determine the surgical strategy for PJI of the hip (Oe, et al., 2015, pp. 19–25). One-stage revision THA was recommended for patients scoring >9 points. Patients with scoring ≤4 points had an 83% risk of recurrent infection.

Criterion	Points (total = 12)
1.General condition	
-Poor (ASA ≥3)	0
-Moderate (DM, steroid, autoimmune disease)	1
-Good	2
2.Duration of infection, number of past operations	
-Past operation ≥2 (including osteotomy, debridement)	0
-Late infection	1
-Early or delay infection	2
3.Present wound complication	
-Sinus tract, abscess	0
-Slightly damaged (reddish, warmth)	1
-Intact	2
4.Presence of microorganisms	
-MRSA, gram-negative organisms	0
-Unknown	1
-Antibiotic sensitive organism	2
5.CRP level (mg/L)	
- >50	0
- 5– 50	1
- <50	2
6.Necessity for bone grafting	
-Necessary	0
-Unnecessary	2

### Salvage Procedures

Salvage procedures (resection arthroplasty, arthrodesis, and amputation) must be considered in

situations with multiple failures of PJI treatment and in patients who have an unacceptably high risk of recurrent infection, limited function of the joint after



reimplantation, an immunocompromised host, or too poor general condition to withstand a repeated operation (Lichstein, et al., 2014, pp. 108-111; Osmon, et al., 2013, pp. e1-e25; Parvizi, et al., 2012, p. e104).

Resection arthroplasty involves the removal of all components without subsequent reimplantation. This technique has a high cure rate, but the functional outcome is very poor (Mabry Tad, 2011, pp. 257-266). Knee arthrodesis, or fusion, has the goal of achieving a painless, stable joint, but motion is sacrificed. Amputation is the ultimate salvage procedure for a failed exchange arthroplasty. It is indicated for infection that is beyond any other surgical remedies and where arthrodesis is not possible (Ailabouni Ramez, & Hooper Gary, 2015, pp. 1-8).

#### **Fungal PJI**

Fungal PJI is extremely rare, with an incidence less than 1% of all reported PJI. To date, there have been 91 cases of fungal PJI reported (Gebauer, et al., 2014, pp. 112-114). Knowledge regarding fungal PJI management has been drawn from case reports and small case series, which means we still lack appropriate diagnostic tools and, usually, any suitable treatment. Most commonly, fungal PJI is caused by *Candida* spp., of which *C. albicans* was the most frequent mentioned in the literature (Goff Thomas, Rambani, & NG Aaron, 2014, pp. 169-174). Fungal PJI should be considered as a possibility in a patient who has a clinical history suspicious for PJI with predisposing factors to fungal PJI. Predisposing host factors for fungal PJI are an immunocompromised state, malignant disease, inappropriate use of antibiotics, diabetes mellitus, and autoimmune disease. Lacking any specific diagnostic tool for fungal PJI, a selective fungal media with

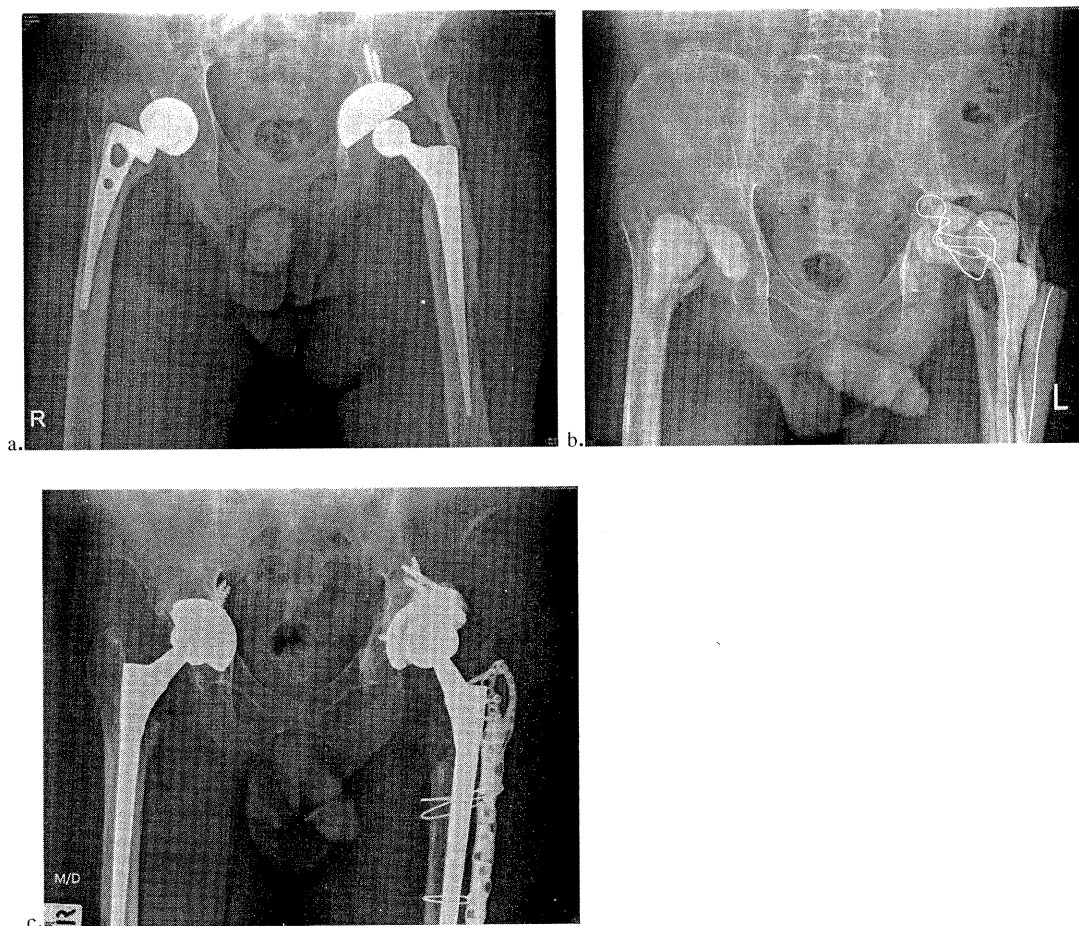
extend incubation period or a polymerase chain reaction (PCR) may be reasonable alternative diagnostic tools.

On the basis of current literature, two-stage revision surgery with an administration of Amphotericin (either oral or intravenous) for a minimum of six weeks is the recommended treatment to manage fungal PJI (Gebauer, et al., 2014, pp. 112-114). Anyhow, the success rate of two-stage exchange arthroplasty in treating fungal PJI is far lower than in treating bacterial PJI (Gebauer, et al., 2014, pp. 112-114; Goff Thomas, et al., 2014, pp. 169-174). Antifungal bone cement seems to be a safe and potentially effective adjunctive treatment in two-stage revision arthroplasty for treating fungal PJI (Goff Thomas, et al., 2014, pp. 169-174).

#### **Author Preference**

The author prefers to perform debridement and irrigation with prosthesis retention and an exchange of all modular parts, followed by six weeks of a pathogen-specific intravenous antibiotic for early postoperative or acute hematogenously spreading PJI that has a duration of infection less than 4 weeks. For patients with delayed treatment (>4 weeks), a high-virulence pathogen, or loosened implant, the author recommends two-stage revision surgery, which is also the surgical treatment of choice for chronic PJI. After removing all implants and foreign bodies, the author prefers to mix 4 gm of Vancomycin per one batch (40 gm) of cement in creating a handmade dynamic spacer. Six weeks of intravenous, pathogen-specific antibiotic followed by an antibiotic holiday of at least 3 months are prescribed before proceeding to the second stage (Figure 4).

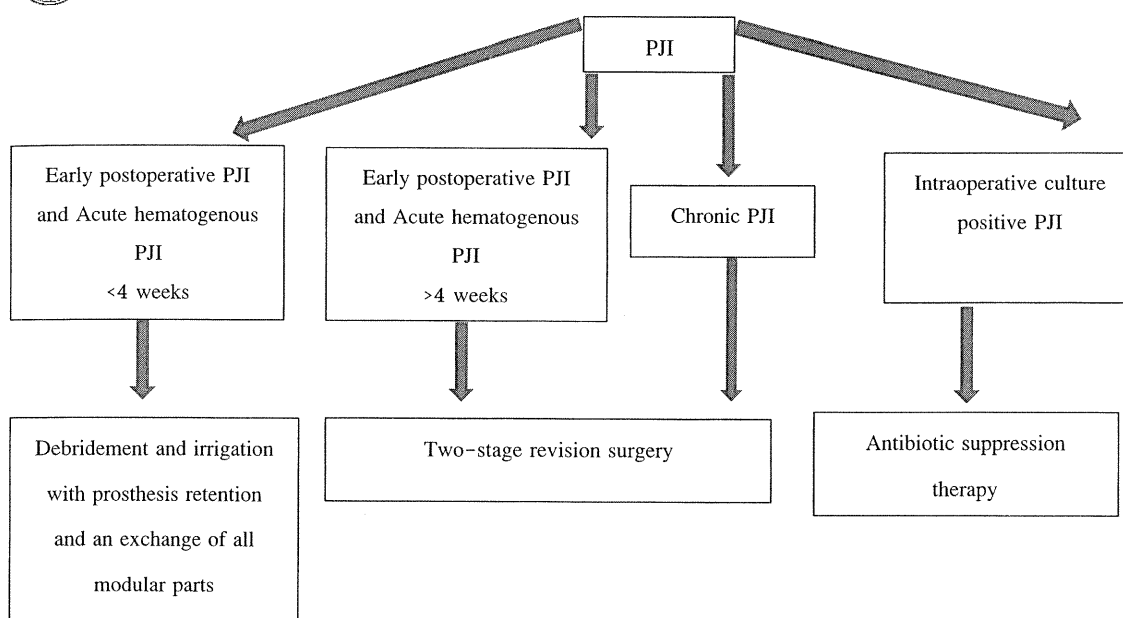




**Figure 4** A two-stage revision arthroplasty (a) An AP radiograph of 65 years old patients with chronic PJI both hip, he had sinus tract at both hip joint longer than 16 years. (b) After treated with first-stage implants removal and hand-mold antibiotic spacer, followed by 6 weeks of intravenous Vancomycin. (c) A second-stage reimplantation was performed after a 3 months of antibiotic holiday.

If the persistence of infection is questionable during the reimplantation phase, the intraoperative frozen section is used to determine the status of the infection. If the frozen section is unavailable, another two-stage revision surgery is the author's preference.

Antibiotic-suppression therapy is indicated for patients with intraoperative culture-positive PJI and patients who are unable to tolerate surgery (Figure 5). The author has no experience with fungal PJI.



**Figure 5** Author preferred treatment algorithm of PJI

#### Culture-Negative PJI

The prevalence of culture-negative PJI ranges between 7% and 12%; the most important cause of which is administration of an antibiotic before obtaining a culture sample (Parvizi, Erkocak, & Della Valle, 2014, pp. 430–436). To minimize the rate of culture-negative PJI, all antibiotics must be withdrawn at least two weeks before culture sampling or until the pathogen is identified. Multiple culture samples from the prosthesis–bone interface should be obtained. Additional recommendations are to prolong the incubation period of the samples and to use specialized media for atypical organisms, such as fungi (Parvizi, et al., 2014, pp. 430–436). PCR is an alternative method for identifying the causative organism in culture-negative PJI patients, but it also increases the rate of false positive PJI.

#### Bacterial Biofilm and PJI

The biofilm theory of microbiological growth has been thoroughly examined and has firm support from scientific evidence. By this theory, bacteria grow and exist in two different states: (1) a biofilm state and (2) a planktonic form. As biofilm, unicellular bacteria can grow and survive in a complex matrix

that they themselves produce and which provides protection and offers shelter. In planktonic form, bacteria behave as usual unicellular organisms (Hoiby, et al., 2015).

The distinction between biofilm and planktonic forms had a major effect on the treatment of bacterial infection. In the biofilm state, bacteria do not have the ability to spread the infection, but they are well protected from the immune system and resistant to antibiotics. On the other hand, bacteria in the planktonic phenotype have the ability to roam and invade to other sites, while being at the same time susceptible to antibiotics and the immune system (Arnold, Shirtliff, & Stoodley, 2013, pp. 2223–2229).

An association between bacterial biofilm and PJI was proposed three decades ago by Gristina and Costerton, but the theory has only recently gained prominence (Tzeng, et al., 2014, pp. 192–200). The properties of the two phenotypes of bacteria, biofilm and planktonic, can explain the characteristic differences between acute and chronic PJI. In acute PJI, bacteria are in the planktonic form. They act as free-floating pathogens that actively and aggressively



spread the infection. The inflammation response of the patient (including swelling, erythema, warmth, and fever) is a response against planktonic bacteria. These free-floating planktonic bacteria are a reason why, compared to chronic PJI, acute PJI has higher incidence of culture-positive infections and a superior eradication rate. Chronic PJI, on the other hand, which involves the biofilm phenotype, has fewer symptoms, lower incidence of identifying the causative pathogen from culture, and inferior eradication rates (Arnold, et al., 2013, pp. 2223-2229).

Modern laboratory tests are develop aiming for isolate the causative bacteria from biofilm. PCR and sonication of explanted components have been clinically applied to improve microbiological diagnosis of chronic PJI (Ailabouni Ramez, & Hooper Gary, 2015, pp. 1-8; Janz, et al., 2013, pp. 931-936). Although PCR and sonication of explanted material can increase sensitivity, they also increase the rate of false-positive cultures, which should be kept in mind. Other techniques, such as fluorescence, in situ hybridization, and DNA microarrays, are still being studied in vitro (Tzeng, et al., 2014, pp. 192-200).

The principle for successful treatment of PJI in the context of biofilm theory is simply to propose that "any surgical treatment will definitely fail if that treatment cannot adequately eradicate the biofilm at the infection site" (Diaz-Ledezma, Higuera, & Parvizi, 2013, pp. 2374-2382; Tzeng, et al., 2014, pp. 192-200). As an example of this concept, simple debridement and irrigation with prosthesis retained as a treatment for chronic PJI has an unacceptable rate of failure because of bacterial biofilm on the remaining prosthesis. The current concept for treating biofilms is a combination of a high-dose antibiotic with known anti-biofilm agents, such as Colistin, Meropenem, Azithromycin, and

Rifampin (Hoiby, et al., 2015; Restrepo, et al., 2014, pp. 104-107; Tzeng, et al., 2014, pp. 192-200). Quorum quenching, bacteriophages, ultrasound, and electrotherapy are next-generation biofilm treatments; these are still under investigation.

### Prevention of PJI

Though prevention is important, most surgeons pay little attention to this step. It is easier to identify patients at high-risk for PJI preoperatively, adopting appropriate prevention strategies in these patients followed by close postoperative monitoring before the development of PJI, than to confront this catastrophic complication. Comorbidities of patients, such as morbid obesity, poor glycemic control, rheumatoid arthritis, myocardial infarction, atrial fibrillation, higher ASA score and previous PJI, along with a longer hospital stay, simultaneous bilateral surgery, long duration of surgery, and superficial surgical infection postoperatively are currently the most common risk factors for PJI (Ailabouni Ramez, & Hooper Gary, 2015, pp. 1-8; Chen, et al., 2014, pp. 119-128; Garvin, & Konigsberg, 2011, pp. 1167-1175; Matar, et al., 2010, pp. 36-46).

Optimization of patient status preoperatively is crucial for ensuring an excellent result after total joint replacement. A malnourished patient, as define as serum transferrin < 200 mg/dL, serum albumin < 3.5 g/dL, and total lymphocyte count < 1500 cells/mm<sup>3</sup>, has a five to sevenfold higher risk of developing wound complications (Matar, et al., 2010, pp. 36-46). An internal medicine consultant should participate in a multidisciplinary approach for improving the status of patient health and controlling patient comorbidities.

Prophylactic antibiotic administration within 30-60 minutes prior to the operation can reduce the risk of wound infection by 8% (Matar, et al., 2010, pp. 36-46). First- and second- generation cephalosporin is the antibiotic of choice, because it



has good tissue penetration and has excellent effect against *Staphylococcus* and *Streptococcus*. Vancomycin and Clindamycin might be alternative antibiotics in patients with a history of penicillin allergy (Ailabouni Ramez, & Hooper Gary, 2015, pp. 1-8; Hansen, et al., 2014, pp. 29-48). Patients who are current MRSA carriers or who were treated previously for MRSA infection in the first-stage revision are also recommended for Vancomycin administration (Hansen, et al., 2014, pp. 29-48). Postoperative antibiotics longer than 24 hours and dual prophylaxis antibiotic are not recommended.

Some evidence shows that preoperative skin preparation with chlorhexidine can reduce the infection rate of the surgical site from 2% to 0.5% (Kapadia Bhveen, McElroy Mark, Pivec Robert, Daley Jacqueline, & Mont Michael, 2013, pp. 83-86). There is no significant difference between various skin-cleansing agents, but a combination of antiseptic and alcohol may be more successful than other skin-preparation agents (Tokarski, et al., 2014, pp. 26-28). At the end of the operation, diluting betadine lavage before closure has been a reported technique that can reduce the incidence of PJI (Brown, Cipriano, Moric, Sporer, & Della Valle, 2012, pp. 27-30).

Persistent wound drainage postoperatively—more than 2x2 cm area of gauze continuing longer than 72 hours—is significant and should be managed with wound care (Ghanem, et al., 2014, pp. 84-92). For a wound with persistent drainage greater than 5-7 days, reoperation and then thorough irrigation and debridement with exchange of all modular parts should be considered (Ghanem, et al., 2014, pp. 84-92).

## Conclusion

Even though an algorithm for PJI diagnosis and guidelines for PJI management have been established on the basis of contemporary knowledge, infection after total joint arthroplasty remains an extremely disastrous complication, challenging to manage. Besides clinical presentation and a plain radiograph, synovial fluid analysis along with serum ESR and CRP are important basic investigatory tools for PJI diagnosis.

Onset and duration of the infection will determine the appropriate treatment. Early postoperative infection and acute, hematogenously spreading infections that have had symptoms for fewer than four weeks are properly treated by debridement and irrigation with exchange of all modular components. Late presentation and chronic infection (> 4 weeks), meanwhile, should be treated by two-stage exchange arthroplasty. Antibiotic suppression alone is reserved for intraoperative, culture-positive PJI and for patients that seem unable to tolerate an invasive surgical treatment.

Proper diagnosis and surgical intervention combined with a microbiologically specific antibiotic treatment are recommended in order to improve the final results for a patient with PJI, as well as to improve diagnostic accuracy.

## References

- Aggarwal, V. K., Higuera, C., Deirmengian, G., Parvizi, J., & Austin, M. S. (2013). Swab cultures are not as effective as tissue cultures for diagnosis of periprosthetic joint infection. *Clin Orthop Relat Res*, 471(10), 3196-3203. doi: 10.1007/s11999-013-2974-y



- Ailabouni Ramez, J. A., & Hooper Gary. (2015). Peri-prosthetic infection - An algorithmic approach to diagnosis and management. *Orthopaedics and Trauma*, 29(1), 1-8.
- Alijanipour, P., Bakhshi, H., & Parvizi, J. (2013). Diagnosis of periprosthetic joint infection: the threshold for serological markers. *Clin Orthop Relat Res*, 471(10), 3186-3195. doi: 10.1007/s11999-013-3070-z
- Arnold, W. V., Shirtliff, M. E., & Stoodley, P. (2013). Bacterial biofilms and periprosthetic infections. *J Bone Joint Surg Am*, 95(24), 2223-2229.
- Ascione, T., Pagliano, P., Mariconda, M., Rotondo, R., Balato, G., & Toro, A., et al. (2015). Factors related to outcome of early and delayed prosthetic joint infections. *J Infect*, 70(1), 30-36. doi: 10.1016/j.jinf.2014.07.008S0163-4453(14) 00204-7 [pii]
- Bedair, H., Ting, N., Jacovides, C., Saxena, A., Moric, M., & Parvizi, J., et al. (2011). The Mark Coventry Award: diagnosis of early postoperative TKA infection using synovial fluid analysis. *Clin Orthop Relat Res*, 469(1), 34-40. doi: 10.1007/s11999-010-1433-2
- Brown, N. M., Cipriano, C. A., Moric, M., Sporer, S. M., & Della Valle, C. J. (2012). Dilute betadine lavage before closure for the prevention of acute postoperative deep periprosthetic joint infection. *J Arthroplasty*, 27(1), 27-30. doi: 10.1016/j.arth.2011.03.034S0883-5403(11)00146-X [pii]
- Chen Antonia, D. V. C., & Rao Nalini, P. J. (2012). Treatment of the Infected Total Knee. *Oper Tech Orthop*, 22, 236-246.
- Chen, A., Haddad, F., Lachiewicz, P., Bolognesi, M., Cortes, L. E., & Franceschini, M., et al. (2014). Prevention of late PJI. *J Arthroplasty*, 29(2 Suppl), 119-128. doi: 10.1016/j.arth.2013.09.051S0883-5403(13)00734-1 [pii]
- Christensen, C. P., Bedair, H., Della Valle, C. J., Parvizi, J., Schurko, B., & Jacobs, C. A. (2013). The natural progression of synovial fluid white blood-cell counts and the percentage of polymorphonuclear cells after primary total knee arthroplasty: a multicenter study. *J Bone Joint Surg Am*, 95(23), 2081-2087. doi: 10.2106/JBJS.L.016461787283 [pii]
- Citak, M., Argenson, J. N., Masri, B., Kendoff, D., Springer, B., & Alt, V., et al. (2014). Spacers. *J Arthroplasty*, 29(2 Suppl), 93-99. doi: 10.1016/j.arth.2013.09.042S0883-403(13)723-7 [pii]
- Corona, P., Gil, E., Guerra, E., Soldado, F., Amat, C., & Flores, X., et al. (2012). Percutaneous interface biopsy in dry-aspiration cases of chronic periprosthetic joint infections: a technique for preoperative isolation of the infecting organism. *Int Orthop*, 36(6), 1281-1286. doi: 10.1007/s00264-011-1418-0
- Cummins, N. W. (2014). CORR Insights: Is synovial C-reactive protein a useful marker for periprosthetic joint infection? *Clin Orthop Relat Res*, 472(12), 4004-4005. doi: 10.1007/s11999-014-3882-5



- Della Valle, C., Parvizi, J., Bauer, T. W., Dicesare, P. E., Evans, R. P., & Segreti, J., et al. (2010). Diagnosis of periprosthetic joint infections of the hip and knee. *J Am Acad Orthop Surg*, 18(12), 760-770. doi: 18/12/760 [pii]
- Diagnosis of periprosthetic joint infection after unicompartmental knee arthroplasty. (2012). *J Arthroplasty*, 27(8 Suppl), 46-50. doi: 10.1016/j.arth.2012.03.033S0883-5403(12)00189-1 [pii]
- Diaz-Ledezma, C., Higuera, C. A., & Parvizi, J. (2013). Success after treatment of periprosthetic joint infection: a Delphi-based international multidisciplinary consensus. *Clin Orthop Relat Res*, 471(7), 2374-2382. doi: 10.1007/s11999-013-2866-1
- Elgeidi, A., Elganainy, A. E., Abou Elkhier, N., & Rakha, S. (2014). Interleukin-6 and other inflammatory markers in diagnosis of periprosthetic joint infection. *Int Orthop*, 38(12), 2591-2595. doi: 10.1007/s00264-014-2475-y
- Friedrich, M. J., Randau, T. M., Wimmer, M. D., Reichert, B., Kuberra, D., & Stoffel-Wagner, B., et al. (2014). Lipopolysaccharide-binding protein: a valuable biomarker in the differentiation between periprosthetic joint infection and aseptic loosening? *Int Orthop*, 38(10), 2201-2207. doi: 10.1007/s00264-014-2351-9
- Galliera, E., Drago, L., Marazzi, M. G., Romano, C., Vassena, C., & Corsi Romanelli, M. M. (2015). Soluble urokinase-type plasminogen activator receptor (suPAR) as new biomarker of the prosthetic joint infection: Correlation with inflammatory cytokines. *Clin Chim Acta*, 441, 23-28. doi: 10.1016/j.cca.2014.11.029S0009-8981(14)00534-8 [pii]
- Garvin, K. L., & Konigsberg, B. S. (2011). Infection following total knee arthroplasty: prevention and management. *J Bone Joint Surg Am*, 93(12), 1167-1175.
- Gebauer, M., Frommelt, L., Achan, P., Board, T. N., Conway, J., & Griffin, W., et al. (2014). Management of fungal or atypical periprosthetic joint infections. *J Arthroplasty*, 29(2 Suppl), 112-114. doi: 10.1016/j.arth.2013.09.049S0883-5403(13)00732-8 [pii]
- Ghanem, E., Heppert, V., Spangehl, M., Abraham, J., Azzam, K., & Barnes, L., et al. (2014). Wound management. *J Arthroplasty*, 29(2 Suppl), 84-92. doi: 10.1016/j.arth.2013.09.041S0883-5403(13)00722-5 [pii]
- Goff Thomas, A. J., Rambani, R., & NG Aaron, B. (2014). Current concepts in the management of periprosthetic fungal joint infection using antifungal bone cement. *Current Orthopaedic Practice*, 25(2), 169-174. doi: 10.1097/BCO.0000000000000074
- Haasper, C., Buttaro, M., Hozack, W., Aboltins, C. A., Borens, O., & Callaghan, J. J., et al. (2014). Irrigation and debridement. *J Arthroplasty*, 29(2 Suppl), 100-103. doi: 10.1016/j.arth.2013.09.043S0883-5403(13)00724-9 [pii]



- Hansen, E., Belden, K., Silibovsky, R., Vogt, M., Arnold, W. V., & Bicanic, G., et al. (2014). Perioperative antibiotics. *J Arthroplasty*, 29(2 Suppl), 29-48. doi: 10.1016/j.arth.2013.09.030S0883-5403(13)00711-0 [pii]
- Hansen, E., Tetreault, M., Zmistowski, B., Della Valle, C. J., Parvizi, J., & Haddad, F. S., et al. (2013). Outcome of one-stage cementless exchange for acute postoperative periprosthetic hip infection. *Clin Orthop Relat Res*, 471(10), 3214-3222. doi: 10.1007/s11999-013-3079-3
- Hoell, S., Borgers, L., Gosheger, G., Dieckmann, R., Schulz, D., & Gerst, J., et al. (2015). Interleukin-6 in two-stage revision arthroplasty: what is the threshold value to exclude persistent infection before re-implantation? *Bone Joint J*, 97-B(1), 71-75. doi: 10.1302/0301-620X.97B1.3380297-B/1/71 [pii]
- Hoiby, N., Bjarnsholt, T., Moser, C., Bassi, G. L., Coenye, T., & Donelli, G., et al. (2015). ESCMID guideline for the diagnosis and treatment of biofilm infections 2014. *Clin Microbiol Infect*, In Press, Corrected Proof, Available online 14 January 2015. doi: S1198-743X(14)00090-1 [pii] 10.1016/j.cmi.2014.10.024
- Janz, V., Wassilew, G. I., Hasart, O., Matziolis, G., Tohtz, S., & Perka, C. (2013). Evaluation of sonicate fluid cultures in comparison to histological analysis of the periprosthetic membrane for the detection of periprosthetic joint infection. *Int Orthop*, 37(5), 931-936. doi: 10.1007/s00264-013-1853-1
- Kapadia Bhavien, I. K., McElroy Mark, Pivec Robert, Daley Jacqueline, & Mont Michael. (2013). Advance pre-operative chlorhexidine preparation reduces periprosthetic infections following total joint arthroplasty. *Seminars in Arthroplasty*, 24, 83-86.
- Kuzyk, P. R., Dhotar, H. S., Sternheim, A., Gross, A. E., Safir, O., & Backstein, D. (2014). Two-stage revision arthroplasty for management of chronic periprosthetic hip and knee infection: techniques, controversies, and outcomes. *J Am Acad Orthop Surg*, 22(3), 153-164. doi: 10.5435/JAAOS-22-03-15322/3/153 [pii]
- Lee Kyung-Jae, G. S. (2014). Identification of periprosthetic joint infection after total hip arthroplasty. *Journal of Orthopaedic Translation*, 3(1), 1-5.
- Lenski, M., & Scherer, M. A. (2014). Synovial IL-6 as inflammatory marker in periprosthetic joint infections. *J Arthroplasty*, 29(6), 1105-1109. doi: 10.1016/j.arth.2014.01.014S0883-5403(14)00036-9 [pii]
- Lichstein, P., Gehrke, T., Lombardi, A., Romano, C., Stockley, I., & Babis, G., et al. (2014). One-stage vs two-stage exchange. *J Arthroplasty*, 29(2 Suppl), 108-111. doi: 10.1016/j.arth.2013.09.048S0883-5403(13)00731-6 [pii]
- Liu, J. Z., Saleh, A., Klika, A. K., Barsoum, W. K., & Higuera, C. A. (2014). Serum inflammatory markers for periprosthetic knee infection in obese versus non-obese patients. *J Arthroplasty*, 29(10), 1880-1883. doi: 10.1016/j.arth.2014.07.005S0883-5403(14)00470-7 [pii]





- Mabry Tad, H. A. (2011). Management of the Infected Total Knee Arthroplasty. In B. D. Lieberman Jay, Azar Frederick (Ed.), *ADVANCED RECONSTRUCTION: Knee* (pp. 257-266). Rosemont, IL: American Academy of Orthopaedics Surgeons.
- Manner, P. (2013). CORR Insights(R): outcome of one-stage cementless exchange for acute postoperative periprosthetic hip infection. *Clin Orthop Relat Res*, 471(10), 3223-3224. doi: 10.1007/s11999-013-3180-7
- Matar, W. Y., Jafari, S. M., Restrepo, C., Austin, M., Purtill, J. J., & Parvizi, J. (2010). Preventing infection in total joint arthroplasty. *J Bone Joint Surg Am*, 92(Suppl 2), 36-46. doi: 10.2106/JBJS.J.0104692/Supplement\_2/36 [pii]
- Minassian, A. M., Osmon, D. R., & Berendt, A. R. (2014). Clinical guidelines in the management of prosthetic joint infection. *J Antimicrob Chemother*, 69(Suppl 1), i29-35. doi: 10.1093/jac/dku253dku 253 [pii]
- O'Toole, P., Osmon, D., Soriano, A., Berdal, J. E., Bostrum, M., & Franco-Cendejas, R., et al. (2014). Oral antibiotic therapy. *J Arthroplasty*, 29(2 Suppl), 115-118. doi: 10.1016/j.arth.2013.09.050S0883-5403(13)00733-X [pii]
- Oe, K., Iida, H., Ueda, N., Nakamura, T., Okamoto, N., Ueda, Y. (2015). Pre-operative scoring system to determine the surgical strategy for periprosthetic hip infection. *Int Orthop*, 39(1), 19-25. doi: 10.1007/s00264-014-2493-9
- Osmon, D. R., Berbari, E. F., Berendt, A. R., Lew, D., Zimmerli, W., & Steckelberg, J. M., et al. (2013). Diagnosis and management of prosthetic joint infection: clinical practice guidelines by the Infectious Diseases Society of America. *Clin Infect Dis*, 56(1), e1-e25. doi: 10.1093/cid/cis803cis 803 [pii]
- Parvizi, J., Adeli, B., Zmistowski, B., Restrepo, C., & Greenwald, A. S. (2012). Management of periprosthetic joint infection: the current knowledge: AAOS exhibit selection. *J Bone Joint Surg Am*, 94(14), e104. doi: 10.2106/JBJS.K.014171216 215 [pii]
- Parvizi, J., Erkocak, O. F., & Della Valle, C. J. (2014). Culture-negative periprosthetic joint infection. *J Bone Joint Surg Am*, 96(5), 430-436. doi: 10.2106/JBJS.L.017931832014 [pii]
- Parvizi, J., & Gehrke, T. (2014). Definition of periprosthetic joint infection. *J Arthroplasty*, 29(7), 1331. doi:10.1016/j.arth.2014.03.009 S0883-5403 (14)00166-1 [pii]
- Parvizi, J., Jacovides, C., Antoci, V., & Ghanem, E. (2011). Diagnosis of periprosthetic joint infection: the utility of a simple yet unappreciated enzyme. *J Bone Joint Surg Am*, 93(24), 2242-2248. doi: 10.2106/JBJS.J.01413
- Parvizi, J., Zmistowski, B., Berbari, E. F., Bauer, T. W., Springer, B. D., & Della Valle, C. J., et al. (2011). New definition for periprosthetic joint infection: from the Workgroup of the Musculoskeletal Infection Society. *Clin Orthop Relat Res*, 469(11), 2992-2994. doi: 10.1007/s11999-011-2102-9



- Restrepo, C., Schmitt, S., Backstein, D., Alexander, B. T., Babic, M., & Brause, B. D., et al. (2014). Antibiotic treatment and timing of reimplantation. *J Arthroplasty*, 29(2 Suppl), 104-107. doi: 10.1016/j.arth.2013.09.047S0883-5403(13)00730-4 [pii]
- Ronde-Oustau, C., Diesinger, Y., Jenny, J. Y., Antoni, M., Gaudias, J., & Boeri, C., et al. (2014). Diagnostic accuracy of intra-articular C-reactive protein assay in periprosthetic knee joint infection--a preliminary study. *Orthop Traumatol Surg Res*, 100(2), 217-220. doi: 10.1016/j.otsr.2013.10.017S1877-0568(14)00033-4 [pii]
- Segawa, H., Tsukayama, D. T., Kyle, R. F., Becker, D. A., & Gustilo, R. B. (1999). Infection after total knee arthroplasty. A retrospective study of the treatment of eighty-one infections. *J Bone Joint Surg Am*, 81(10), 1434-1445.
- Shanmugasundaram, S., Ricciardi, B. F., Briggs, T. W., Sussmann, P. S., & Bostrom, M. P. (2014). Evaluation and Management of Periprosthetic Joint Infection-an International, Multicenter Study. *HSS J*, 10(1), 36-44. doi: 10.1007/s11420-013-9366-49366 [pii]
- Sheehan, E. (2015). CORR Insights((R)): The Alpha-defensin Test for Periprosthetic Joint Infection Outperforms the Leukocyte Esterase Test Strip. *Clin Orthop Relat Res*, 473(1), 204-205. doi: 10.1007/s11999-014-3794-4
- Sherrell, J. C., Fehring, T. K., Odum, S., Hansen, E., Zmistowski, B., & Dennis, A., et al. (2011). The Chitranjan Ranawat Award: fate of two-stage reimplantation after failed irrigation and debridement for periprosthetic knee infection. *Clin Orthop Relat Res*, 469(1), 18-25. doi: 10.1007/s11999-010-1434-1
- Stammers, J., Kahane, S., Ranawat, V., Miles, J., Pollock, R., & Carrington, R. W., et al. (2015). Outcomes of infected revision knee arthroplasty managed by two-stage revision in a tertiary referral centre. *Knee*, 22(1), 56-62. doi: 10.1016/j.knee.2014.10.005S0968-0160(14)00253-1 [pii]
- Tetreault, M. W., Wetters, N. G., Moric, M., Gross, C. E., & Della Valle, C. J. (2014). Is synovial C-reactive protein a useful marker for periprosthetic joint infection? *Clin Orthop Relat Res*, 472(12), 3997-4003. doi: 10.1007/s11999-014-3828-y
- Tokarski, A. T., Blaha, D., Mont, M. A., Sancheti, P., Cardona, L., & Cotacio, G. L., et al. (2014). Perioperative skin preparation. *J Arthroplasty*, 29(2 Suppl), 26-28. doi: 10.1016/j.arth.2013.09.029S0883-5403(13)00710-9 [pii]
- Toossi, N., Adeli, B., Rasouli, M. R., Huang, R., & Parvizi, J. (2012). Serum white blood cell count and differential do not have a role in the diagnosis of periprosthetic joint infection. *J Arthroplasty*, 27(8 Suppl), e51. doi: 10.1016/j.arth.2012.03.021S0883-5403(12)00177-5 [pii]
- Triantafyllopoulos, G. K., Poultsides, L. A., Zhang, W., Sculco, P. K., Ma, Y., & Sculco, T. P. (2014). Periprosthetic Knee Infections Treated with Irrigation and Debridement: Outcomes and Preoperative Predictive Factors. *J Arthroplasty*, In Press, Corrected Proof, Available online 25 October 2014. doi: S0883-5403(14)00809-2 [pii] 10.1016/j.arth.2014.10.026



- Tzeng, A., Tzeng, T. H., Vasdev, S., Korth, K., Healey, T., & Parvizi, J., et al. (2014). Treating periprosthetic joint infections as biofilms: key diagnosis and management strategies. *Diagn Microbiol Infect Dis*, 81(3), 192–200. doi: S0732-8893(14)00447-7 [pii] 10.1016/j.diagmicrobio.2014.08.018
- Wetters, N. G., Berend, K. R., Lombardi, A. V., Morris, M. J., Tucker, T. L., & Della Valle, C. J. (2012). Leukocyte esterase reagent strips for the rapid diagnosis of periprosthetic joint infection. *J Arthroplasty*, 27(8 Suppl), 8–11. doi: 10.1016/j.arth.2012.03.037S0883-5403(12)00214-8 [pii]
- Zeller, V., Lhotellier, L., Marmor, S., Leclerc, P., Krain, A., & Graff, W., et al. (2014). One-stage exchange arthroplasty for chronic periprosthetic hip infection: results of a large prospective cohort study. *J Bone Joint Surg Am*, 96(1), e1. doi: 10.2106/JBJS.L.014511790478 [pii]
- Zhao, X., Guo, C., Zhao, G. S., Lin, T., Shi, Z. L., & Yan, S. G. (2013). Ten versus five polymorphonuclear leukocytes as threshold in frozen section tests for periprosthetic infection: a meta-analysis. *J Arthroplasty*, 28(6), 913–917. doi: 10.1016/j.arth.2012.10.015S0883-5403(13)00074-0 [pii]
- Zmistowski, B., Della Valle, C., Bauer, T. W., Malizos, K. N., Alavi, A., & Bedair, H., et al. (2014). Diagnosis of periprosthetic joint infection. *J Arthroplasty*, 29(2 Suppl), 77–83. doi: 10.1016/j.arth.2013.09.040S0883-5403(13)00721-3 [pii]
- Zmistowski, B., Restrepo, C., Huang, R., Hozack, W. J., & Parvizi, J. (2012). Periprosthetic joint infection diagnosis: a complete understanding of white blood cell count and differential. *J Arthroplasty*, 27(9), 1589–1593. doi: 10.1016/j.arth.2012.03.059S0883-5403(12)00236-7 [pii]

