

Treatment Outcomes of Transcatheter Closure in Common Congenital Heart Disease: Success Rate and Short-term Complications

Worawan Jittham¹ and Woranan Sanguanwong²

¹Department of Pediatrics; ²Cardiothoracic Technology, Faculty of Medicine, Naresuan University, Phitsanulok, Thailand

Correspondence: Worawan Jittham, M.D., Department of Pediatrics, Faculty of Medicine, Naresuan University, Mueng Phitsanulok, Phitsanulok, Thailand. E-mail: ann_pitlok@yahoo.com

Received: June 21, 2021;
Revised: August 18, 2021;
Accepted: August 20, 2021

© The Author(s) 2022. Open Access



This article is licensed under a Creative Commons Attribution 4.0 International License, which permits use, sharing, adaptation, distribution and reproduction in any medium or format, as long as you give appropriate credit to the original author(s) and the source, provide a link to the Creative Commons licence, and indicate if changes were made.

ABSTRACT

OBJECTIVE This study aimed to investigate treatment outcomes, including success rates and any short-term complications of transcatheter closure in common congenital heart disease (CHD), ventricular septal defect (VSD), atrial septal defect (ASD) and patent ductus arteriosus (PDA) at our tertiary cardiac center.

METHODS This retrospective study was conducted at Naresuan University Hospital, Thailand. We enrolled patients for the analysis who had undergone transcatheter device closure (VSD, ASD and PDA) from October 2011 through May 2018. Treatment outcome success is defined as complete closure at 1 day, 1 month and 6 months following the procedure. Major complications associated with transcatheter device closure such as device embolization, arrhythmia, cardiac tamponade, thromboembolism, cardiac erosion and death were also collected.

RESULTS Ninety-four patients, ranging from children to adults, were enrolled. ASD, PDA and VSD device closure was done in 45, 40 and 9 patients, respectively. Overall success at 1 day, 1 month and 6 months following the procedure were 87.3, 92.1 and 96.8%, respectively. There were 2 complications reported, one thromboembolism and one first-degree atrioventricular block (AVB).

CONCLUSIONS Transcatheter closure in common congenital heart diseases provides good treatment outcomes and is safe for all age groups, from children to adults, with only a small number of major complications.

KEYWORDS congenital heart disease, transcatheter closure, treatment outcome, ASD device closure, VSD device closure, PDA device closure

INTRODUCTION

Congenital heart disease (CHD) is a common birth defect which varies in complexity from a simple single to a fatal complex CHD lesion. The prevalence is 9.4:1,000 live births. The three most common types of CHD are ventricular septal defect (VSD), atrial septal defect (ASD) and patent ductus arteriosus (PDA) (1). Standard treatment guidelines for these defects, either surgical or transcatheter closure, have been published for several decades (2). Transcatheter device closure was introduced several years ago as a treatment for PDA (3), followed

by ASD (4) and VSD (5). Outcomes of transcatheter device closure in previous studies have been reported to be more favorable, to result in faster recovery and to be less invasive than surgical treatment, especially ASD and VSD which require open-heart surgery techniques (6,7). Although several studies have reported excellent success rates with defect closure using the transcatheter technique, there are some limitations as the device may not be suitable for all patients due to anatomical variation and a defect size not appropriate to currently available devices (6–11). Transcatheter device closure

complications include device embolization, arrhythmias or conduction problems, cardiac tamponade, thromboembolism, stroke and death. There are some specific complications for related to each procedure, e.g., device erosion which has been found in ASD devices (6), coarctation of the aorta after PDA device closure (9, 10) and complete atrioventricular block after VSD device closure (11). This study aimed to investigate treatment outcomes, including success rates and any short-term complications, of transcatheter closure in common CHD (VSD, ASD and PDA) at our tertiary cardiac center.

METHODS

This retrospective analysis was conducted at Naresuan University Hospital, Thailand. We enrolled patients diagnosed with VSD, ASD and PDA who had undergone transcatheter device closure between October 2011 and May 2018. Patients' demographic data (age, sex) was collected by hospital medical record review. The diagnosis of congenital heart disease for each patient and the decision regarding device size selection were made by a cardiologist using standard echocardiography. Catheterization reports, including procedure time, fluoroscopic time and evidence of pulmonary hypertension, were also collected. Treatment outcomes, including success rate and any complications, were evaluated. Success, defined as "complete closure" reflected with no residual lesion observed on echocardiography, was evaluated by a cardiologist at 1 day, 1 month and 6 months after device closure. Major complications associated with transcatheter device closure, including device embolization, arrhythmia, cardiac tamponade, thromboembolism, cardiac erosion and death, were collected.

Patients who underwent transcatheter closure for any defect and who were reported as complete closure at post-procedure day 1 were defined as "immediately successful closure". The relative proportion of the size of device used and the size of the defect was calculated as a percentage and compared between patients with immediate successful closures and those with residual lesions. In this study, a Cocoon® device (Vascular Innovations Co., Ltd., Nonthaburi, Thailand) was chosen based on cost effec-

tiveness compared to the other brands with no conflict of interest involved. All procedures performed involving human participants were conducted in accordance with the ethical standards of the Naresuan University Institutional Review Board (NU-IRB) and the 1964 Helsinki Declaration as amended or comparable ethical standards. Informed consent was obtained from all participants involved in the study.

Statistical analysis

Continuous data are presented as mean and standard deviation or median and maximum with minimum for data distribution. Categorical data are shown as frequency and percentage.

RESULTS

A total of 135 patients diagnosed with correctable cardiac lesion who underwent transcatheter device closure from October 2011 through May 2018 at Naresuan University Hospital were eligible for the study. Among those patients, three were referred for surgery including one child with ASD with absence of posterior rim on transesophageal echocardiography (TEE), one adult with a large, distended ASD of 34 mm in diameter which was too large for any device. The third patient referred for surgery was a child diagnosed with PDA with significant coarctation of the aorta identified by aortogram under fluoroscopy with a pressure gradient of 25 mmHg. Patients with incomplete data or who were lost to follow-up were also excluded. A total of 94 patients who had a complete transcatheter closure procedure were enrolled in the study. ASD device closure was done in 45 patients; PDA device and VSD device closure was done in 40 and 9 patients, respectively (Figure 1). The types of ASD and PDA devices were Cocoon septal and duct Occluder. The VSD devices included 5 Cocoon VSD Aneurysm and 4 Cocoon VSD Membranous and Muscular devices. Patients' age distribution was 0-17 years (67%), 18-49 years (14.9%) and in 50 years and above (18.1%). Among the patients aged 0-17 years, PDA device closure was the most common procedure, whereas an ASD device was most frequently used in patients aged 18-49 years and aged 50 years and above. Pulmonary

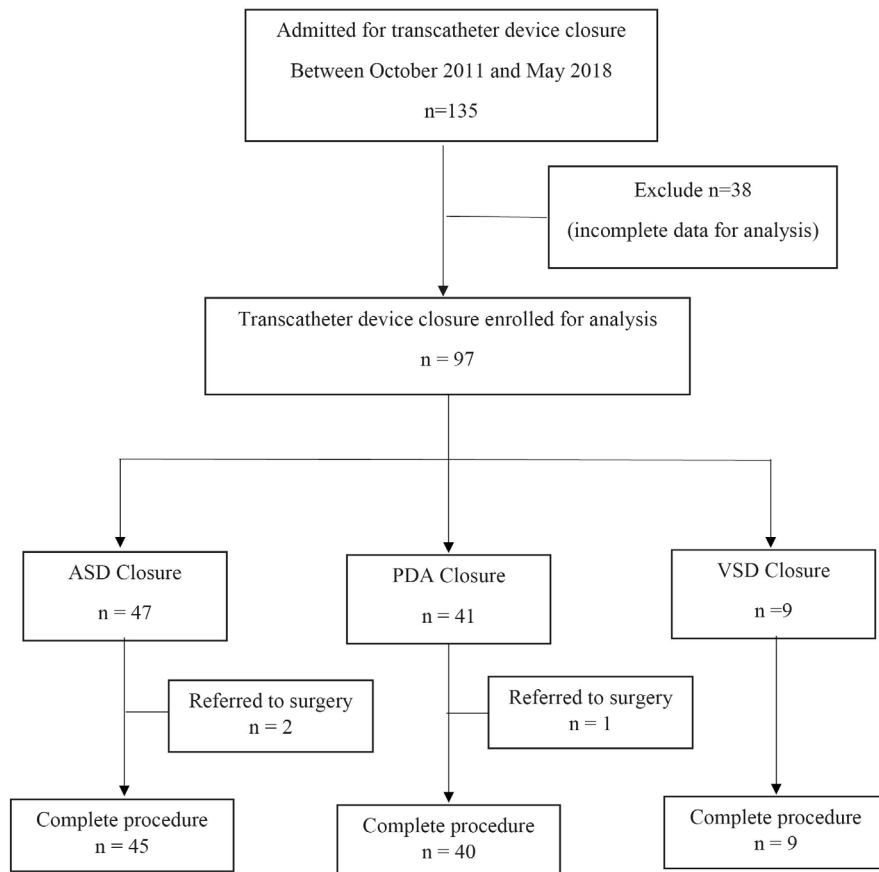


Figure 1. Consort diagram. Characteristics of study participants

ASD, atrial septal defect; VSD, ventricular septal defect; PDA, patent ductus arteriosus

hypertension was reported in half the patients with ASD devices (46.7%). The mean procedure time with ASD devices was 65.8 (± 32.1) minutes and the median fluoroscopy time was 7 minutes (range 2.3 to 46.3 minutes). For PDA devices, the mean procedure time was 71.1 (± 25.5) minutes and the median fluoroscopy time was 11.5 minutes (range 0.7 to 80.2 minutes). For VSD devices, the mean procedure time was 107.9 (± 36.5) minutes and for fluoroscopy time was 21.5 minutes (range 9.2 to 62.3 minutes) (Table 1).

Success rate and complications

The overall success rate at 1 day, 1 month and 6 months for all transcatheter closures were 87.3, 92.1 and 96.8%, respectively. For ASD devices, the success rate at 1 day, 1 month and 6 months were 91.1, 93.3 and 95.5%, respectively. PDA device success rates at 1 day, 1 month and 6 months were 82.5, 95 and 97.5%, respectively. VSD devices success rates at 1 day, 1 month and 6 months were 77.8, 77.8 and 100%, respec-

tively. Only two patients experienced complications after the procedure. One patient, aged 49, reported thromboembolism which manifested as stroke with symptoms of dysarthria without any weakness immediately after ASD device closure. The second patient, aged 11, had a first-degree atrioventricular block (AVB) at the 6-month follow up for ASD device closure. There were no reports of device embolization, cardiac erosion, complete atrioventricular block or death (Table 2).

Among patients with immediately successful closure, the mean device to defect size proportions ratio, expressed as percent, were 117.8% for ASD, 170.2% for PDA and 111.6% for VSD devices. The proportion ratio of the size of the device to the size of the defect was slightly larger among the immediately successful closure group than those with residual lesions (Table 3).

DISCUSSION

Transcatheter closure in common CHD has been used for several decades because of

Table 1. Patient characteristics

	All (n=94)	ASD (n=45)	PDA (n=40)	VSD (n=9)
Age (%)				
0–17 years	63 (67.0)	19 (42.2)	36 (90.0)	8 (88.9)
18–49 years	14 (14.9)	10 (22.2)	3 (7.5)	1 (11.1)
≥50 years	17 (18.1)	16 (35.6)	1 (2.5)	0
Female (%)	63 (67)	30 (66.7)	31 (77.5)	2 (22.2)
Procedure time (minutes) mean (±SD)	72.1 (±31.9)	65.8 (±32.1)	71.1 (±25.5)	107.9 (±36.5)
Fluro time (minutes)	10.1	7	11.5	21.5
median (max:min)	(0.7 : 80.2)	(2.3 : 46.3)	(0.7 : 80.2)	(9.2 : 62.3)
Pulmonary hypertension (%)	31 (32.9)	21 (46.7)	7 (17.5)	3 (33.3)

ASD, atrial septal defect; VSD, ventricular septal defect; PDA, patent ductus arteriosus

Table 2. Treatment outcomes: success rates and complications

After procedure	All (%)	ASD (%)	PDA (%)	VSD (%)
1 day	82 (87.3)	41 (91.1)	33 (82.5)	7 (77.8)
1 month	87 (92.1)	42 (93.3)	38 (95.0)	7 (77.8)
6 months	91 (96.8)	43 (95.5)	39 (97.5)	9 (100)
Complications				
Thromboembolism	1	1	–	–
Atrioventricular block	1	1	–	–
Device embolization	–	–	–	–
Cardiac erosion	–	–	–	–
Death	–	–	–	–

ASD, atrial septal defect; VSD, ventricular septal defect; PDA, patent ductus arteriosus

Table 3. Mean device to lesion size (percent) and immediate treatment outcome (after 1 day)

Treatment outcome	Device: lesion size (%)		
	ASD	PDA	VSD
Complete closure	117.8 (n=41)	170.2 (n=33)	111.6 (n=8)
Incomplete closure	115.9 (n=4)	164.9 (n=7)	85.7 (n=1)

ASD, atrial septal defect; VSD, ventricular septal defect; PDA, patent ductus arteriosus

its efficiency and because it is less invasive compared to surgical techniques. Especially in younger children, infants or patients with underlying conditions, the transcatheter technique has been shown to be more beneficial than referring patients for an operation (6, 7, 12). Our study found good outcomes with few reported complications with the transcatheter technique for closing any common defect in all age groups which is in accord with previous studies (6–10).

Only two major complications were reported at the 6-month follow up, one AVB and one ischemic stroke. Rhythm disturbance is a rare complication following ASD device closure. There have been some reports of first or third-degree AVB following the procedure which were

treated surgically by device removal and with corticosteroids (13–15). The mechanism of this rhythm disturbance may be any direct trauma to the conduction system, e.g., an intraoperative finding in an ASD device removal operation showed right atrium disk compression at the triangle of Koch with a small hematoma (13), or any inflammation. However, from the previous reports VSD devices were found to be more complicated frequently associated with AVB, especially perimembranous type VSD according due to the anatomical location close to the bundle of His, than any other type of device. Our study found only one case of hemodynamically stable, first-degree AVB following ASD device closure. A recent study of 70 Saudi Arabian children who underwent VSD device

closure found 2.9% of the cases experienced transient conduction abnormalities (bradycardia, asystole or complete AVB), while another 2.9% had complete AVB following the procedure that required a permanent pacemaker or surgical intervention (16). A recent meta-analysis, however, found no significant difference in the incidence of complete AVB between the transcatheter and surgical closure techniques (12). Our study did not find any complications among patients with VSD devices, although this may be due to the limited number of cases.

Thromboembolism is a common complication in both diagnostic and interventional cardiac catheterization. A previous study in New York reported an incidence of 0.18% for stroke events following coronary angiography. Our study reported one case of an ischemic stroke event following ASD device closure. Heparinization, frequent catheter aspiration and flushing are standard guidelines for prevention of thromboembolism events during the procedure (17).

Another interesting complication is atrial wall erosion after ASD device closure. A recent case series found that 88% of patients with atrial wall erosion had an aortic rim deficiency.

The United States Food and Drug Administration Panel Review has labeled a retro-aortic rim that is lesser than 5 mm in diameter as a relative contraindication for ASD device closure (19). Although our study did not report any atrial wall erosion events during the 6-months follow-up period, we continuously monitor for this event.

Comparison of the ratio of the size of the device used and the size of the defect showed that patients with immediately successful closure had received larger devices compared to those with residual lesions. This may help in provides provisional guidance for choosing the proper size of device for each patient by considering the individual defect size; however, due to the limited number of patients in this study, additional investigation is needed to establish conclusive guidelines.

CONCLUSIONS

Transcatheter closure in common congenital heart diseases results in successful and safe

treatment outcomes in all age groups, from children to adults with only a small number of major complications. A larger device size relative to the size of the lesion may result in immediate complete closure. However, currently available devices may not suitable for all patients due to anatomical variations and large defect sizes relative to the size of the devices.

ACKNOWLEDGEMENTS

We like to express our gratitude to the hospital personnel for medical records and data collection. This study was supported by research funding from Naresuan University.

CONFLICTS OF INTEREST STATEMENT

The authors have each completed the International Committee of Medical Journal Editors Form for uniform disclosure of potential conflicts of interest. No authors have any potential conflict of interest to disclose.

REFERENCES

1. Liu Y, Chen S, Zühlke L, Black GC, Choy MK, Li N, et al. Global birth prevalence of congenital heart defects 1970–2017: updated systematic review and meta-analysis of 260 studies. *Int J Epidemiol*. 2019;48:455–63.
2. Baumgartner H, De Backer J, Babu-Narayan SV, Budts W, Chessa M, Diller GP, et al. 2020 ESC Guidelines for the management of adult congenital heart disease. *Eur Heart J*. 2021;42:563–645.
3. Porstmann W, Wierny L, Warnke H. Closure of persistent ductus arteriosus without thoracotomy. *Ger Med Mon*. 1967;12:259–61.
4. King TD, Thompson SL, Steiner C, Mills NL. Secundum atrial septal defect. Nonoperative closure during cardiac catheterization. *JAMA*. 1976;235:2506–9.
5. Lock JE, Block PC, McKay RG, Baim DS, Keane JF. Transcatheter closure of ventricular septal defects. *Circulation*. 1988;78:361–8.
6. O'Byrne ML, Levi DS. State-of-the-art atrial septal defect closure devices for Congenital heart. *Interv Cardiol Clin*. 2019;8:11–21.
7. Liu S, Chen F, Ding X, Zhao Z, Ke W, Yan Y, et al. Comparison of results and economic analysis of surgical and transcatheter closure of perimembranous ventricular septal defect. *Eur J Cardiothorac Surg*. 2012;42:e157–62.
8. Faccini A, Butera G. Atrial septal defect (ASD) device trans-catheter closure: limitations. *J Thorac Dis*. 2018;10:S2923–30.
9. Baruteau AE, Hascoët S, Baruteau J, Boudjemline Y, Lambert V, Angel CY, et al. Transcatheter clo-

- sure of patent ductus arteriosus: past, present and future. *Arch Cardiovasc Dis.* 2014;107:122–32.
10. P S, Jose J, George OK. Contemporary outcomes of percutaneous closure of patent ductus arteriosus in adolescents and adults. *Indian Heart J.* 2018;70:308–15.
 11. Morray BH. Ventricular septal defect closure devices, techniques, and outcomes. *Interv Cardiol Clin.* 2019;8:1–10.
 12. Saurav A, Kaushik M, Mahesh Alla V, White MD, Satpathy R, Lanspa T, et al. Comparison of percutaneous device closure versus surgical closure of perimembranous ventricular septal defects: A systematic review and meta-analysis. *Catheter Cardiovasc Interv.* 2015;86:1048–56.
 13. Sato J, Kato A, Takeda S, Nishikawa H. Case report: atrioventricular block after transcatheter atrial septal closure using the Figulla® Flex II ASD occluder. *Catheter Cardiovasc Interv.* 2019;93:E298–301.
 14. Chantepie A, Lefort B, Soulé N, Bonnefoy R, Labarthe F. Atrioventricular block after transcatheter atrial septal defect closure using the Amplatzer septal occluder®. *Arch Pediatr.* 2013;20:1333–6.
 15. Al-Anani SJ, Weber H, Hijazi ZM. Atrioventricular block after transcatheter ASD closure using the Amplatzer septal occluder: risk factors and recommendations. *Catheter Cardiovasc Interv.* 2010;75:767–72.
 16. Khoshhal SQ, Al-Mutairi MB, Alnajjar AA, Morsy MM, Salem SS, Al-Muhaya M, et al. Transcatheter device closure of ventricular septal defects in children: a retrospective study at a single cardiac center. *Ann Saudi Med.* 2020;40:396–402.
 17. Wong SC, Minutello R, Hong MK. Neurological complications following percutaneous coronary interventions (a report from the 2000–2001 New York State Angioplasty Registry). *Am J Cardiol.* 2005;96:1248–50.
 18. Amin Z, Hijazi ZM, Bass JL, Cheatham JP, Hellenbrand WE, Kleinman CS. Erosion of Amplatzer septal occluder device after closure of secundum atrial septal defects: review of registry of complications and recommendations to minimize future risk. *Catheter Cardiovasc Interv.* 2004;63:496–502.
 19. Mallula K, Amin Z. Recent changes in instructions for use for the Amplatzer atrial septal defect occluder: How to incorporate these changes while using transesophageal echocardiography or intracardiac echocardiography. *Pediatr Cardiol.* 2012;33:995–1000.